

Morphological abnormalities in the Striped panray, *Zanobatus schoenleinii* (Zanobatidae) from the coast of Senegal (Eastern Tropical Atlantic)

Anormalidades morfológicas en la raya atigrada, *Zanobatus schoenleinii* (Zanobatidae) de la costa de Senegal (Atlántico Tropical Este)

Christian Capapé¹, Sihem Rafrafi-Nouira², Youssouph Diatta³, Almamy Diaby³ and Christian Reynaud^{4*}

¹Laboratoire d'Ichtyologie, Université de Montpellier, case 104, 34095 Montpellier cedex 5, France

²Université de Carthage, Unité de Recherches Exploitation des Milieux Aquatiques, Institut Supérieur de Pêche et d'Aquaculture de Bizerte, BP 15, 7080 Menzel Jemil, Tunisie

³Laboratoire de Biologie Marine, Institut Fondamental d'Afrique Noire, Université Cheikh Anta Diop de Dakar, BP 206, Dakar, Sénégal

⁴Laboratoire Interdisciplinaire en Didactique, Education et Formation, Université de Montpellier, 2 place Marcel Godechot, B.P. 4152, 34092 Montpellier cedex 5, France

*Corresponding author: christian.reynaud@umontpellier.fr

Abstract. - The capture of four abnormal specimens of the Striped panray, *Zanobatus schoenleinii* was reported from shallow coastal waters surrounding the touristic area of Dakar, Republic of Senegal, and among them, some specimens displaying morphological deformities. A specimen exhibited a pectoral non-adherent to the head, a second was tailless, and two specimens displayed scoliosis at level of truncal vertebrae and tail. The abnormalities are described and their causes and consequences herein considered.

Key words: Chondrichthyes, Zanobatidae, *Zanobatus schoenleinii*, pectoral fins, vertebrae, scoliosis, pollution

INTRODUCTION

The Striped panray, *Zanobatus schoenleinii* (Müller & Henle, 1841), is an endemic species known from the eastern tropical Atlantic, where it only occurs between southern Morocco (Lloris & Rucabado 1998), Mauritania (Maurin & Bonnet 1970), Senegal (Diatta *et al.* 2013), Guinea-Bissau (Sanches 1991) and the Gulf of Guinea (Blache *et al.* 1970). *Z. schoenleinii* is both commonly and abundantly captured by artisanal fisheries throughout the coast of Senegal (Cadenat 1951, Séret & Opic 1991, Capapé *et al.* 1995). The species rather inhabits shallow coastal waters, not exceeding 60 m depth (Weigmann 2016). However, according to Stehmann (1981), it can inhabit bottoms until 300 m depth.

Preliminary observations of specimens caught off Oukam, Senegal, showed that size at sexual maturity is reached by males and females at 460 mm and 515 mm in total length (TL), respectively. Additionally, the maximal TL recorded for males

and females were 460 mm, and 560 mm TL, respectively (Capapé *et al.* 1995) in total agreement with Séret & Opic (1991) who noted that maximum TL was 600 mm TL. Females *Z. schoenleinii* are larger than males, displaying a new case of sexual dimorphism in size as it is generally the rule in elasmobranch viviparous species (Mellinger 1989). Some information was also provided about the diet of the species poorly known to date. *Z. schoenleinii* fed all year round on benthic organisms, such crustaceans, mainly amphipods, small bony fishes, molluscs, and worms (Diop 1997).

In the wake of collaboration with experienced fishermen, several *Z. schoenleinii* were collected in shallow coastal waters surrounding the touristic area of Dakar, and among them some of these specimens displayed morphological abnormalities. All collected specimens were transferred at the laboratory for detailed examination, including the abnormal specimens, which are described, and their atypical characteristics commented in the present paper.



MATERIALS AND METHODS

A total of 108 specimens were captured on 25 May 2019 using trammel nets at depth between 5 and 10 m on soft bottom, off Ouakam, an artisanal fishery site located at 5 km north of Dakar, in Cape Verde Peninsula, Republic of Senegal, 14°43'26"N and 17°29'21"W (Fig. 1). Of these 108 specimens, 104 were normal and 4 abnormal. They were measured to the nearest millimeter and weighed to nearest gram. The normal specimens ranged between 253 and 580 mm for total length (TL), 154 and 340 mm for disc width (DW), and weighed between 104 and 1,433 g for total body weight (TBW). All normal specimens were dissected to improve and enlarge studies on reproductive biology and diet of the species. Conversely, a single normal specimen, a large female in perfect morphological condition, was preserved as a reference sample for comparison with the 4 abnormal specimens. These 5 specimens were fixed in 10% buffered formaldehyde, preserved in 75% ethanol and deposited

in the Ichthyological Collection of the Institute Supérieur d'Aquaculture et de Pêche of Bizerte (Tunisia), receiving the catalogue numbers, ISPAB-Zan-sch-01 for a normal specimen and from ISPAB-Zan-sch-03 to ISPAB-Zan-sch-06 for abnormal specimens, respectively.

The relation between DW and TBW was used as a complement following Froese *et al.* (2011), including normal and abnormal specimens to show if these latter were able to develop in the wild similarly to normal specimens. This LWR is $TBW = aDW^b$, and was converted into its linear regression, expressed in decimal logarithmic co-ordinates and correlations were assessed by least-squares regression as: $\log TBW = \log a + b \log DW$: significance of constant b differences was assessed to the hypothesis of isometric growth if $b = 3$, positive allometry if $b > 3$, negative isometry if $b < 3$ (Pauly 1983). These two latter tests were performed by using logistic model StatView 5.0 (SAS institute Cary, NC).

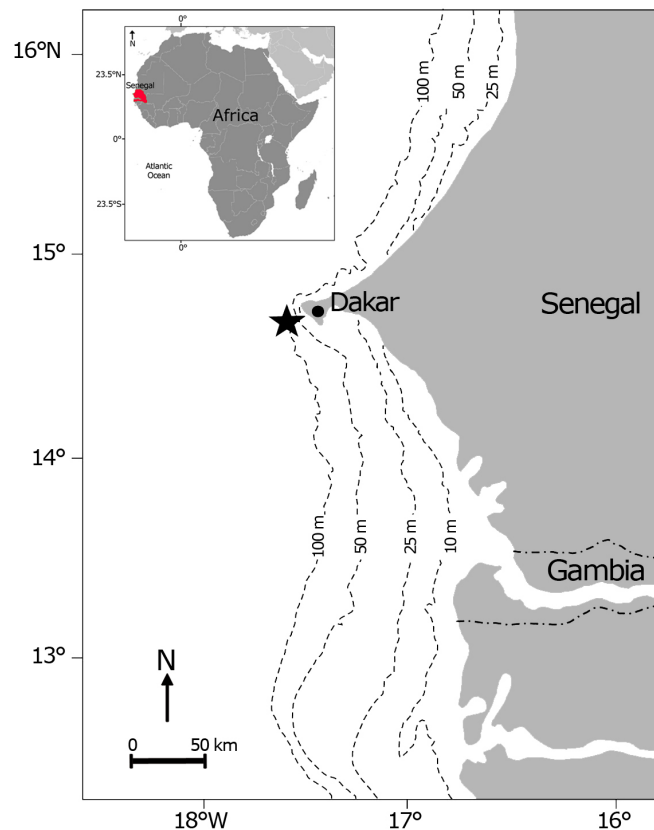


Figure 1. Map of the Senegalese coast indicating the capture site of the specimens of *Zanobatus schoenleinii* (black star) / Mapa de la costa senegalense indicando el sitio de captura de los especímenes de *Zanobatus schoenleinii* (estrella negra)

RESULTS AND DISCUSSION

All specimens were identified as *Zanobatus schoenleinii* due to the following combination of morphological characters: disc sub-circular, wider than long; snout blunt, angle nearly 120° in front; nostrils narrow, anterior valves united across the internarial space; mouth straight; teeth small; spiracles large without folds; dorsal and caudal fins small and rounded; covered by rigid skin; dermal denticles small, of different sizes; a medial row of thorns in disk and tail, and a three rows arranged in arc of circle on each shoulder; dorsal surface brown with dark cross bands with white spots toward pectoral edges. Such description is consistent with that of Garman (1913), Cadenat (1951), Blache *et al.* (1970) and Séret & Opic (1991).

Southwards, a new congeneric species was described in the area, *Zanobatus maculatus* Séret (2016). This species is distinguishable from *Z. schoenleinii* by its smaller size (TL max 358 mm vs. at least 600 mm), a more rounded disc, rhombic in the Striped panray, the presence of numerous dark brown blotches of various sizes vs. wavy medium brown crossbars, a more pronounced dermal armature, and spear-shaped vs. polygonal flat dermal denticles, and lower number of tooth rows.

The normal specimen (ref. ISPAB-Zan-sch-01) was a female of 548 mm of TL, 301 mm of DW, and 1,507 g of weight (Fig. 2). Each abnormal specimen was separately described, as follow.

SPECIMEN REF. ISPAB-ZAN-SCH-03 (FIG. 3)

The specimen was a sub-adult male with developed but flexible claspers. It measured 462 mm TL, 267 mm DW, and weighed 746 g. It exhibited a gap or cleft in on the rostrum which was divided in a left and right side, at its distal end (Fig. 3B). According to Ribeiro-Prado *et al.* (2008), such abnormality occurred in batoid species, and appeared to be more frequent in those with a stronger rostrum, such as skates. It was also reported a bit less in torpedinids and dasyatids (Ribeiro-Prado *et al.* 2008, Mnasri *et al.* 2010). These morphological abnormalities are probably due to a failed fusion of pectoral fins during embryonic development (Bigelow & Schroeder 1953). Additionally, Thorson *et al.* (1983) described the embryonic development of two freshwater stingrays, *Potamotrygon constellata* (Vaillant, 1880) and *P. motoro* (Müller & Henle, 1841). In early stages, the stingray's pectoral fins begin to separate, then it fuses in medium stages and finally the disc is fully formed in near term embryo.



Figure 2. Normal specimen of *Zanobatus schoenleinii* (Ref. ISPAB-Zan-sch-01), from the coast of Senegal. Dorsal surface, scale bar= 100 mm / Espécimen normal de *Zanobatus schoenleinii* (Ref. ISPAB-Zan-sch-01), de la costa de Senegal. Superficie dorsal, barra de escala= 100 mm

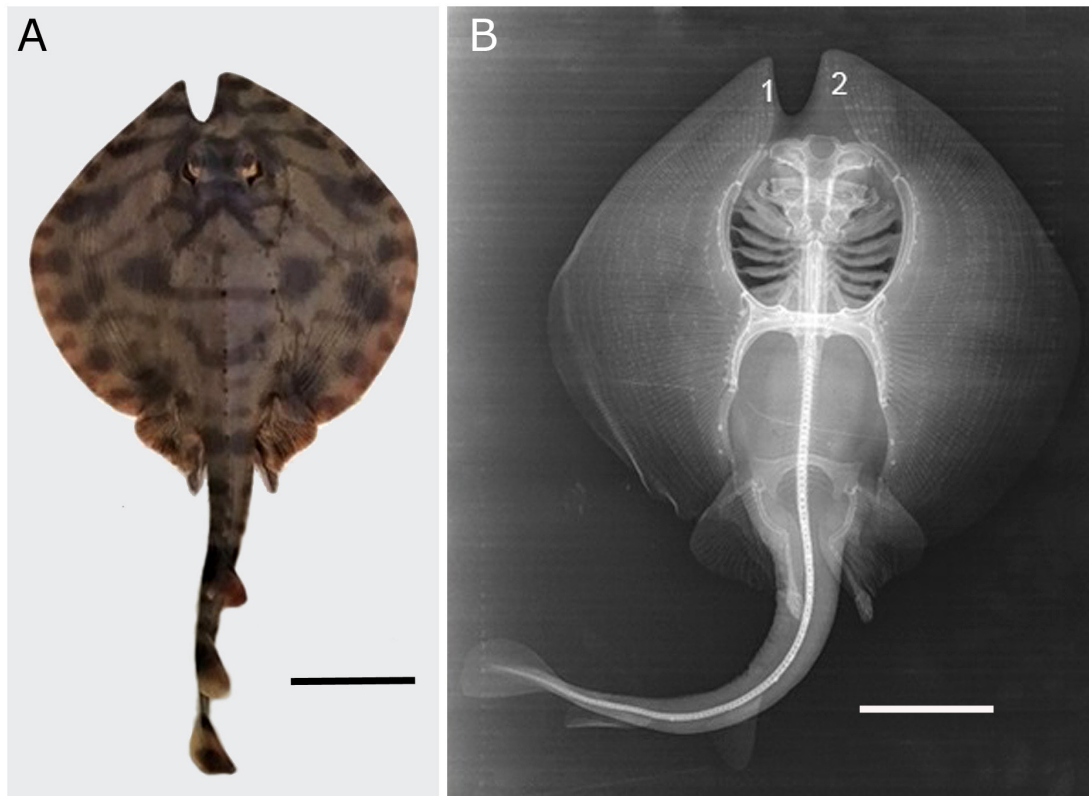


Figure 3. *Zanobatus schoenleinii* (Ref. ISPAB-Zan-sch-03). **A.** Dorsal surface exhibiting a pectoral non-adherent to the head, scale bar= 80 mm. **B.** X-ray radiography, showing the rostrum divided into a left margin (1) and a right margin (2), scale bar= 70 mm / *Zanobatus schoenleinii* (Ref. ISPAB-Zan-sch-03). **A.** Superficie dorsal exhibiendo la aleta pectoral no adherida a la cabeza, barra de escala= 80 mm. **B.** Radiografía, mostrando el rostro dividido en un margen izquierdo (1) y un margen derecho (2), barra de escala= 70 mm

SPECIMEN REF. ISPAB-ZAN-SCH-04 (FIG. 4)

The specimen was a sub-adult female, which measured 295 mm TL, 225 mm DW, and weighed 392 g in TBW. The general shape of the disc was not circular as in normal specimens, but oblong, longer than wide, displaying pectoral margins obviously rounded. The tail was short and stout, second dorsal and caudal fins were lacking. Its distal end is rounded, entirely covered with skin, no visible unhealed scar was observed, suggesting that reduced tail was not the result of an injury but could be considered as a morphological abnormality.

According to Orlov (2010), the presence of tailless specimens, displaying total or partial loss of tail is likely related with predation by sharks or other voracious teleost species feeding. However, it remains difficult to state if such injury occurred recently or during the earlier life stages of the specimen. It is quite frequent especially in stingrays (Tempelman 1965, Ishihara *et al.* 1993), but appeared to be more frequent in skates according to recent observations (Mnasri *et al.* 2009, 2010; Orlov 2010, Capapé *et al.* 2015a, b; Marouani *et al.* 2019).

SPECIMEN REF. ISPAB-ZAN-SCH-05 (FIG. 5)

The specimen was an adult male, which exhibited developed and rigid claspers, obviously longer than the pelvic fin. It measured 486 mm TL, 290 mm DW, and weighed 1,152 g in TBW. The specimen did not display deformation of the disc, which was sub-circular and with left and right pectoral fins symmetrically arranged (Fig. 5A). Conversely, an X-ray radiograph (Fig. 5B) showed a scoliosis which started from the truncal vertebrae and displaying a curvature strongly developed at level of the pelvic girdle. Seven other curvatures are more or less developed and placed along the entire tail from the pelvic girdle to the caudal fin.

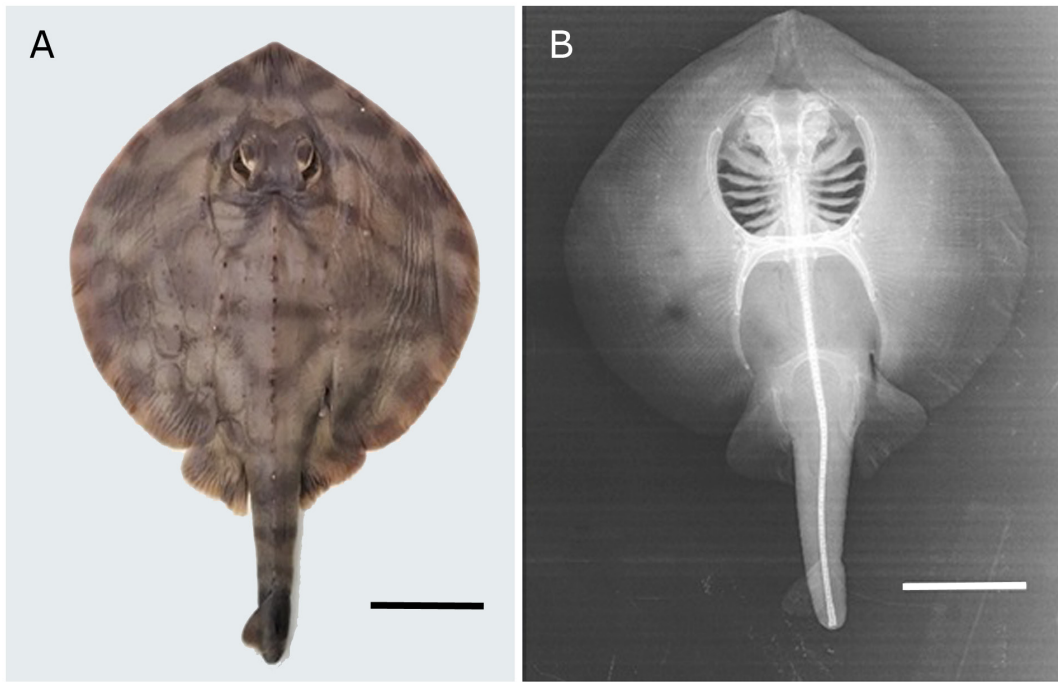


Figure 4. *Zanobatus schoenleinii* (Ref. ISPAB-Zan-sch-04). A. Dorsal surface of tailless specimen, scale bar= 60 mm. B. X-ray radiography, scale bar= 60 mm / *Zanobatus schoenleinii* (Ref. ISPAB-Zan-sch-04). A. Superficie dorsal del espécimen sin cola, barra de escala= 60 mm. B. Radiografía, barra de escala= 60 mm

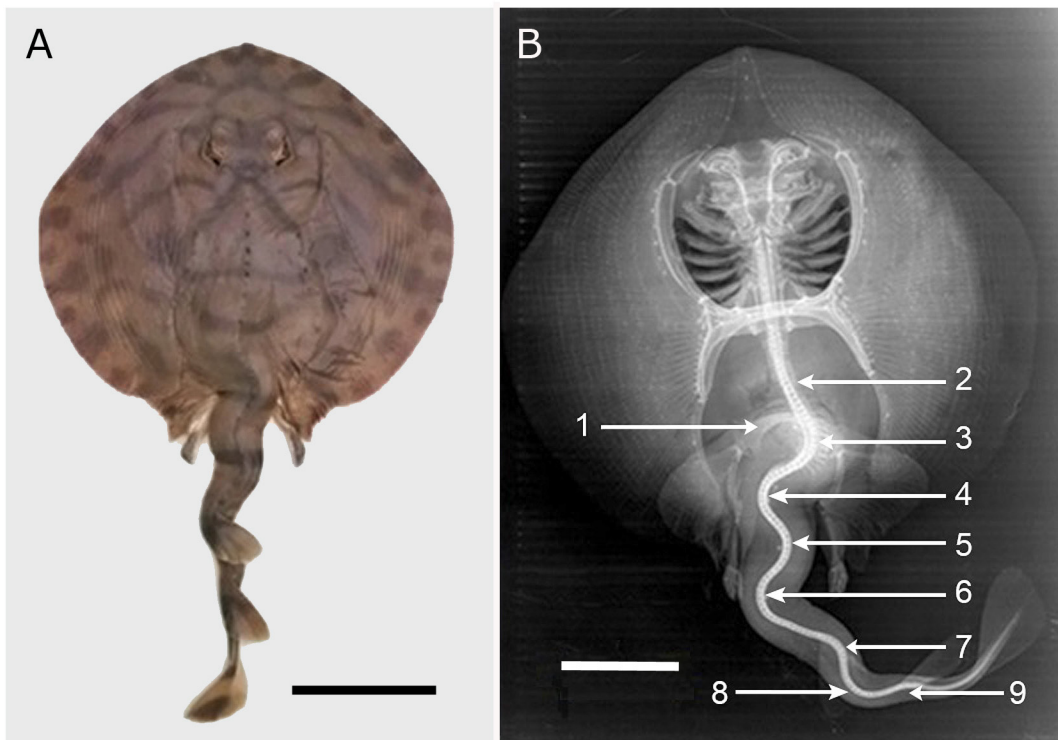


Figure 5. *Zanobatus schoenleinii* (Ref. ISPAB-Zan-sch-05). A. Dorsal surface, scale bar= 80 mm. B. X-ray radiography indicating 1. Pelvic girdle. 2. Scoliosis of truncal vertebrae. 3-9. Tail curvatures, scale bar= 70 mm / *Zanobatus schoenleinii* (Ref. ISPAB- Zan-sch-05). A. Superficie dorsal, barra de escala= 80 mm. B. Radiografía indicando 1. Cintura pélvica. 2. Escoliosis de las vértebras del tronco. 3-9. Curvaturas caudales, barra de escala= 70 mm

SPECIMEN REF. ISPAB-ZAN-SCH-06 (FIG. 6)

The specimen was a sub-adult male, which exhibited developed but flexible claspers. It measured 361 mm TL, 214 mm DW, and weighed 339 g for TBW. The right pectoral was rounded and normally developed. Conversely, the left pectoral exhibited a margin slightly serrated or fringed. The left margin did not display unhealed scar and the unusual shape of this pectoral fin should be considered as an abnormality rather than an injury. Such as the previous specimen (ref. ISPAB-Zan-sch-05), its X-radiography (see Fig. 6B) showed a scoliosis beginning from terminal truncal vertebrae and strongly curved at level of the pelvic girdle. Six other curvatures occurred along the tail, with the proximal curvature being more developed than the other curvatures.

According to Dawson (1964, 1966, 1971) and Dawson & Heal (1971) three categories of abnormalities occur in fish species, albinism total or partial (leucism, piebaldism), hermaphroditism (total or partial), and abnormalities also

called teratological cases or monstrosities (Ribeiro-Prado *et al.* 2018), also recorded in *Zanobatus schoenleinii*. A case of hermaphroditism (Capapé *et al.* 2020a) and three cases of leucism-piebaldism (Diatta *et al.* 2013, Séret 2016, Capapé *et al.* 2020b) were previously reported in the species. In this work, four cases of monstrosities are described.

The relationship size (log DW) versus total body weight (log TBW) is $\log TBW = -6.01 + 3.67 * \log DW$; $r = 0.99$; $n = 108$, $P < 0.01$, and displays a positive allometry although the 4 abnormal specimens were included among the sample (Fig. 7). It appears that these specimens were not considerably affected by a pectoral non-adherent to head and tail abnormalities, with special regard to their development and swimming activities. It is well known that all batoid species use pectoral fins for locomotion as such pattern was previously reported in different species (Mnasri *et al.* 2010, Orlov 2010, Capapé *et al.* 2015 a, b; 2018).

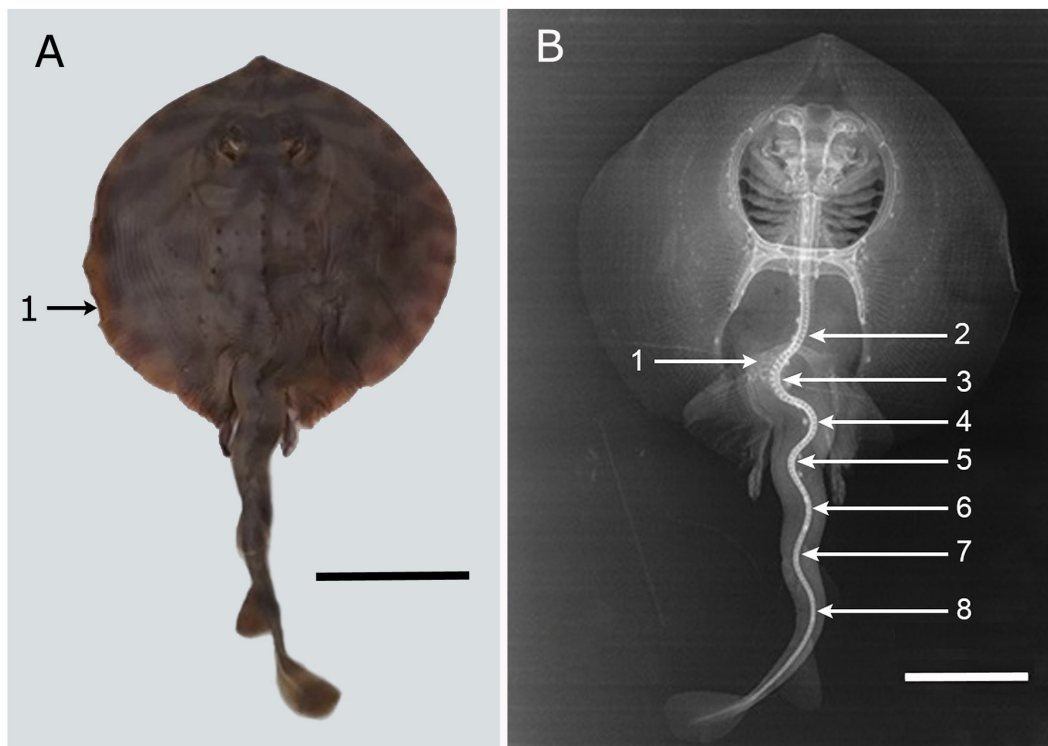


Figure 6. *Zanobatus schoenleinii* (Ref. ISPAB-Zan-sch-06). **A.** Dorsal surface. 1. indicating serrations of the left margin of the pectoral fin, scale bar= 80 mm. **B.** X-ray radiography indicating 1. Pelvic girdle. 2. Scoliosis of truncal vertebrae. 3-8. Tail curvatures, scale bar= 60 mm / *Zanobatus schoenleinii* (Ref. ISPAB-Zan-sch-06). **A.** Superficie dorsal. 1. indica estrías en el margen izquierdo de la aleta pectoral, barra de escala= 80 mm. **B.** Radiografía indicando 1. Cintura pélvica. 2. Escoliosis de las vértebras del tronco. 3-8. Curvaturas caudales, barra de escala= 60 mm

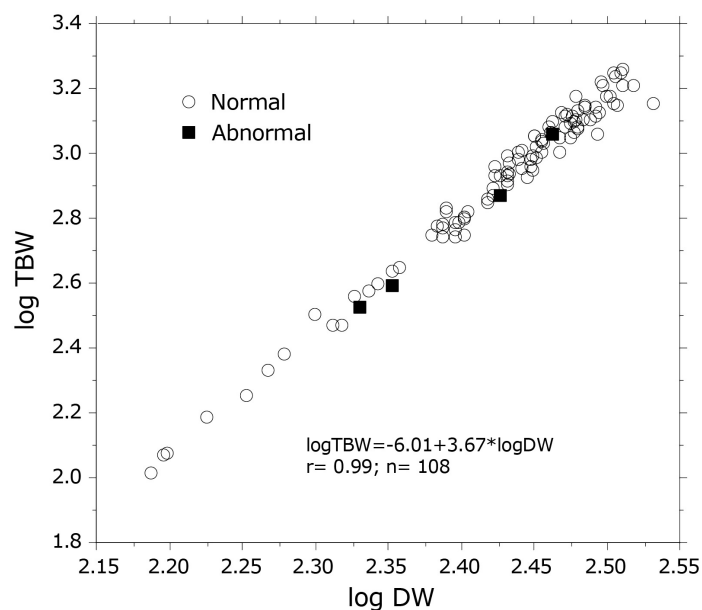


Figure 7. Relationship total body weight (TBW) versus disc width (DW) expressed in logarithmic co-ordinates for normal and abnormal specimens of *Zanobatus schoenleinii* collected from the coast of Senegal / Relación entre peso total (TBW) y ancho del disco (DW), expresada en escala logarítmica para especímenes normales y anormales de *Zanobatus schoenleinii* recolectados en la costa de Senegal

Additionally, other cases of abnormalities in the tail of batoid species were reported. Mnasri *et al.* (2010) recorded, from the Lagoon of Bizerte, a Speckled ray *Raja polystigma* Regan, 1923 with a tail forked at its distal end. Ben Brahim & Capapé (1997) found in the same area a *Torpedo torpedo* (Linnaeus, 1758) having a supernumerary dorsal fin, located at the beginning of the tail, and showing an adipose internal structure. Similarly, Nunes & Piorski (2009) described an adipose dorsal fold on two specimens of the Smooth butterfly ray *Gymnura micrura* (Bloch & Schneider, 1801) from Brazil. On the other hand, Deli Antoni *et al.* (2012) describe a specimen of the Yellownose skate *Dipturus chilensis* (Guichenot, 1848), from southern Argentina, a supplementary appendage, having rather the shape of a dorsal fin, supported by cartilaginous rays, and located on the dorsal surface of the disc. Bureau (1890) noted that similar supplementary appendages were recorded on *Raja clavata* Linnaeus, 1758.

Zanobatus schoenleinii is a viviparous lecithotrophic species *sensu* Hamlett *et al.* (2005) and the embryos developed together in utero, as a consequence, tail deformities could be due to intrauterine pressure exerted by embryos between them (Bensam 1965). According to Bonfil (1989) and Ribeiro-Prado *et al.* (2008), during their development, all embryos are exposed in utero to same growth conditions, and the origin of pre-natal abnormalities are rather related to mutations.

Skeletal deformities are an important factor that downgrade fishery production and have a high economic impact due to the fact that abnormal fishes are not preferred by the consumers (Panagiotis 2015). Deformities are a complex mixture of different bone disorders, and among them nutritional factors such as phosphorus deficiency, vitamin C deficiency, vitamin K deficiency and hypervitaminosis, such unfavourable parameters play an important role in fish farming (Silverstone & Hammell 2002), but a bit less in the wild where the role environmental factors cannot be ruled out such as current velocity, water temperature and large exposure to pollutants (Panagiotis 2015). Diop *et al.* (2012) and Bonnin *et al.* (2016) reported that the coast of Senegal, especially around the touristic area of Dakar is facing to pollutants which is locally increasing since some decades and their impact on the local biodiversity cannot be totally ruled out, the present studied cases remain good instances.

LITERATURE CITED

- Ben Brahim R & C Capapé. 1997.** Nageoire dorsale supplémentaire chez une torpille ocellée, *Torpedo (Torpedo) torpedo* des eaux tunisiennes (Méditerranée Centrale). *Cybium* 21(2): 223-225.
- Bensam P. 1965.** On a freak embryo of the grey shark, *Carcharhinus limbatus* M. & H. *Journal of the Marine Biological Association of India* 7(1): 206-207.

- Bigelow HB & WC Schroeder. 1953.** Sawfishes, guitarfishes, skates and rays. In: Tee-Van J, CM Breder, SF Hildebrand, AE Parr & WC Schroeder (eds). *Fishes of the Western North Atlantic*. Memoirs of the Sears Foundation for Marine Research 2: 1-588.
- Blache J, J Cadenat & J Stauch. 1970.** Clés de détermination des poissons de mer signalés dans l'Atlantique orientale tropicale (entre le 20° parallèle N. et le 15° parallèle S). *Faune Tropicale ORSTOM* 18: 1-479.
- Bonfil R. 1989.** An abnormal embryo of the reef shark *Carcharhinus perezi* (Poey) from Yucatan, Mexico. *Northeast Gulf Science* 10(2): 153-155.
- Bonnin M, I Ly, B Queffelec & M Ngaido. 2016.** Droit de l'environnement marin et côtier au Sénégal, 532 pp. IRD, PRCM, Dakar.
- Bureau L. 1890.** Sur une monstruosité de la raie Estelle (*Raja asterias* Rond.). *Bulletin de la Société Zoologique de France* 14: 313-316.
- Cadenat J. 1951.** Poissons de mer du Sénégal. Initiations Africaines de l'Institut Français d'Afrique Noire de Dakar 3: 1-345.
- Capapé C, M N'Dao & M Diop. 1995.** Données sur la biologie de la reproduction de quatorze espèces de Sélaciens batoïdes capturés dans la région marine de Dakar-Ouakam (Sénégal, Atlantique orientale tropicale). *Bulletin de l'Institut Fondamental d'Afrique Noire Cheikh Anta Diop de Dakar, Série A*, 48: 89-102.
- Capapé C, M Ali, A Saad & C Reynaud. 2015a.** Tail abnormalities in thornback ray *Raja clavata* (Chondrichthyes: Rajidae) from the coast of Syria (eastern Mediterranean). *Cahiers de Biologie Marine* 56(2):155-161.
- Capapé C, M Ali, A Saad, H Alkusaïry & C Reynaud. 2015b.** Atypical characteristics in the longnosed skate *Dipturus oxyrinchus* (Linnaeus, 1785) from the coast of Syria (eastern Mediterranean). *Thalassia Salentina* 37: 71-80.
- Capapé C, I Aydin & O Akyol. 2018.** Morphological deformities and atypical colour pattern in thornback ray, *Raja clavata* (Elasmobranchii: Rajiformes: Rajidae), from Izmir (Turkey, Aegean Sea, Eastern Mediterranean). *Acta Ichthyologica et Piscatoria* 48(3): 261-266.
- Capapé C, Y Diatta, A Diaby, S Rafrafi-Nouira & C Reynaud. 2020a.** An aberrant case of hermaphroditism in striped panray, *Zanobatus schoenleinii* (Zanobatidae) from the coast of Senegal (E-Tropical Atlantic). *Thalassia Salentina* 49: 107-116.
- Capapé C, Y Diatta, A Diaby, S Rafrafi-Nouira & C Reynaud. 2020b.** Leucistic piebald striped panray, *Zanobatus schoenleinii* (Chondrichthyes: Zanobatidae), from the coast of Senegal (eastern tropical Atlantic). *Annales Series. Historia Naturalis* 30(2): 193-200.
- Dawson C. 1964.** A bibliography of anomalies of fishes. *Gulf Research Report* 1: 308-399.
- Dawson C. 1966.** A bibliography of anomalies of fishes. *Gulf Research Report* 2: 169-176.
- Dawson C. 1971.** A bibliography of anomalies of fishes. *Gulf Research Report* 3: 215-239.
- Dawson C & E Heal. 1971.** A bibliography of anomalies of fishes. *Gulf Research Report, Supplement* 3: 215-239.
- Deli Antoni MY, GE Delpiani, SM Delpiani, E Mabragna & JM Díaz de Astarloa. 2012.** An aberrant extra fin in *Zearaja chilensis* (Chondrichthyes: Rajidae). *Cybio* 36(2): 403-405.
- Diatta Y, C Reynaud & C Capapé. 2013.** First case of albinism recorded in striped panray, *Zanobatus schoenleinii* (Chondrichthyes: Platyrrhinidae) from the coast of Senegal (Eastern Tropical Atlantic). *Journal of Ichthyology* 53(11): 1007-1012.
- Diop M. 1997.** Observations sur la systématique et la biologie de la reproduction de trente espèces de poissons élasmobranchés capturés au large de Ouakam (Sénégal, Atlantique orientale tropicale). Dissertation, Faculté des Sciences et Techniques, Université Cheikh Anta Diop de Dakar, Dakar, Sénégal, 90 pp.
- Diop C, D Dewaele, A Toure, M Cabral, F Cazier, M Fall, B Ouddane & A Diouf. 2012.** Study of sediment contamination by trace metals at wastewater discharge points in Dakar (Senegal). *Journal of Water Science* 25(3): 185-299.
- Froese R, AC Tsikliras & KI Stergiou. 2011.** Editorial note on weight-length relations of fishes. *Acta Ichthyologica et Piscatoria* 41(4): 261-263.
- Hamlett WC, G Kormanik, M Storrie, B Stevens & TI Walker. 2005.** Chondrichthyan parity, lecithotrophy and matrotrophy. In: Hamlett WC (ed). *Reproductive biology and phylogeny of chondrichthyes: sharks, rays and chimaeras*, pp. 395-434. Science Publishers, Enfield.
- Ishihara H, K Homma, Y Takeda & JE Randall. 1993.** Redescription, distribution and food habits of the Indo-Pacific dasytid stingray *Himantura granulata*. *Japanese Journal of Ichthyology* 40(1): 23-28.
- Lloris D & J Rucabado. 1998.** Guide FAO d'identification des espèces pour les besoins de la pêche. Guide d'identification des ressources marines vivantes pour le Maroc, 263 pp. FAO, Rome.
- Marouani S, F Ben Jarray, S Karaa & O Jarboui. 2019.** Morphological abnormalities in rajidae species (Chondrichthyes) from the Gulf of Gabès (Tunisia, central Mediterranean Sea): What causes? *Advances in Oceanography and Marine Biology* 1(2): 1-5.
- Maurin C & M Bonnet. 1970.** Poissons des côtes nord-ouest africaines (Campagnes de la "Thalassa", 1962 et 1968). *Revue des Travaux de l'Institut Scientifique et Technique des Pêches Maritimes* 34(2): 125-170.
- Mellinger J. 1989.** Reproduction et développement des Chondrichthyens. *Océanis* 15: 283-303.
- Mnasri N, M Boumaïza & C Capapé. 2009.** Morphological data, observations and occurrence of a rare skate, *Leucoraja circularis* (Chondrichthyes: Rajidae), off the northern coast of Tunisia (central Mediterranean). *Pan-American Journal of Aquatic Sciences* 4(1): 70-78.
- Mnasri N, O El Kamel, M Boumaïza, MM Ben Amor, C Reynaud & C Capapé. 2010.** Morphological abnormalities in two batoid species (Chondrichthyes) from northern Tunisian waters (central Mediterranean). *Annales Series Historia Naturalis* 20(2): 181-190.

- Nunes JL & NM Piorski. 2009.** A dorsal fold in *Gymnura micrura* (Bloch & Schneider, 1801) (Chondrichthyes: Gymnuridae). Brazilian Archives of Biology and Technology 52(2): 479-482.
- Orlov AM. 2010.** Record of a tailless Richardson's ray *Bathyraja richardsoni* (Garrick, 1961) (Rajiformes: Arhynchobatidae) caught off the Mid-Atlantic ridge. Pan-American Journal of Aquatic Sciences 6(4): 232-236.
- Panagiotis B. 2015.** Factors that can lead to the development of skeletal deformities in fishes: a review. Journal of Fisheries Sciences.com 9(3): 17-23.
- Pauly D. 1983.** Some simple methods for assessment of tropical fishes. FAO Fisheries Technical Paper 234: 3-10.
- Ribeiro-Prado CC, MC Oddone, MM Bueno-Gonzalez, A Ferreira de Amorim & C Capapé. 2008.** Morphological abnormalities in skates and rays (Chondrichthyes) from off southeastern Brazil. Arquivos do Ciências do Mar 41(2): 21-28.
- Sanches JG. 1991.** Catálogo dos principais peixes marinhos da República da Guiné-Bissau. Publicações Avulsas do Instituto Nacional de Investigação das Pescas 16: 1-429.
- Séret B. 2016.** *Zanobatus maculatus*, a new species of panray from the Gulf of Guinea, eastern central Atlantic (Elasmobranchii: Batoidea: Zanobatidae). Zootaxa 4161(4): 509-522.
- Séret B & P Opic. 1990.** Poissons de mer de l'ouest Africain tropical, 450 pp. Initiations-Documentations Techniques, ORSTOM, Paris.
- Silverstone AM & L Hammell. 2002.** Spinal deformities in farmed Atlantic salmon. The Canadian Veterinary Journal 43(10): 782-784.
- Stehmann M. 1981.** Poissons batoïdes. In: Fischer W, G Bianchi & WR Scott (eds). Fiches FAO d'identification des espèces pour les besoins de la pêche, Atlantique Centre-Est: Zones de pêche 34, 47 (en partie). Canada Fond de Dépôt, Ministère des Pêcheries et Océans / Organisation des Nations Unies pour l'Alimentation et l'Agriculture, Rome / Ottawa. [FAO Species Identification Sheets for Fishery Purposes, Vol. 1-7: pagination variate]
- Templeman W. 1965.** Some abnormalities in skates (*Raja*) of the Newfoundland area. Journal of the Fisheries Research Board of Canada 22(1): 237-238.
- Thorson TB, JK Langhammer & MI Oettinger. 1983.** Reproduction and development of the South American freshwater stingrays, *Potamotrygon circularis* and *P. motoro*. Environmental Biology of Fishes 9(1): 3-24.
- Weigmann S. 2016.** Annotated check-list of the living sharks, batoids and chimaeras (Chondrichthyes) of the world, with a focus on biogeographical diversity. Journal of Fish Biology 88(3): 837-1037.

Editor: Francisco Concha
 Received 30 October 2020
 Accepted 3 October 2021